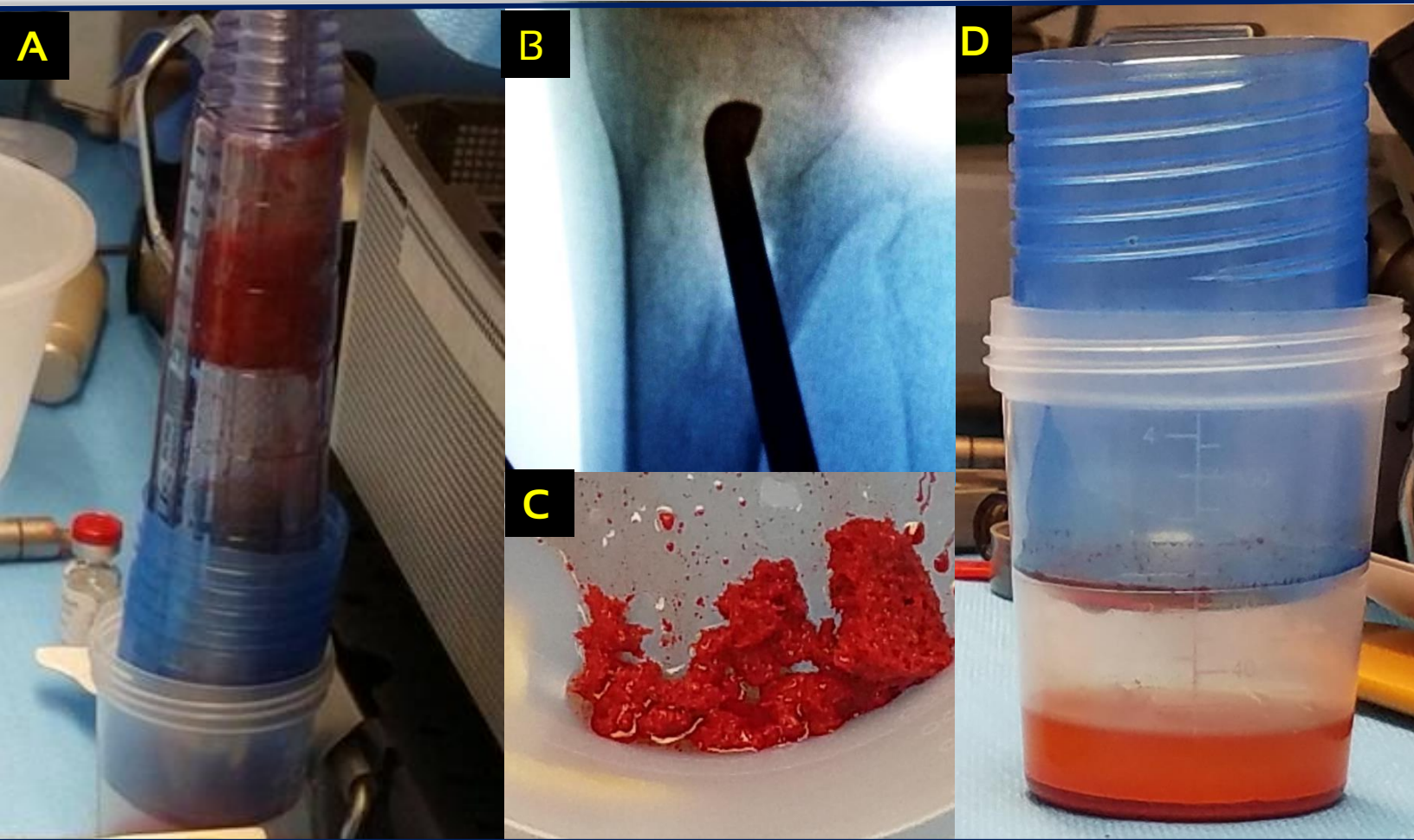


CASE STUDY

Avitus® Bone Harvester PROXIMAL TIBIA HARVEST

- 5 minutes harvest time
- 2.5 cm incision, Patient: 71 YO, M
- 20 CC's of gold-standard cancellous bone
- 20 CC's of gold-standard bone marrow captured
- Graft was successfully used for a Calcaneal Malunion Revision
- **Saved hospital \$2,650 in this case.**



- A) Shows Avitus® 20 CC's of gold standard cancellous bone after marrow was separated being measured inside the Avitus® Handle.
- B) Shows the Avitus® Bone Harvester inside the proximal tibia harvest site under fluoro.
- C) Shows Avitus® 20 CC's of cancellous bone after cancellous bone was retrieved from handle.
- D) Shows Avitus® 20 CC's of bone marrow separated out.