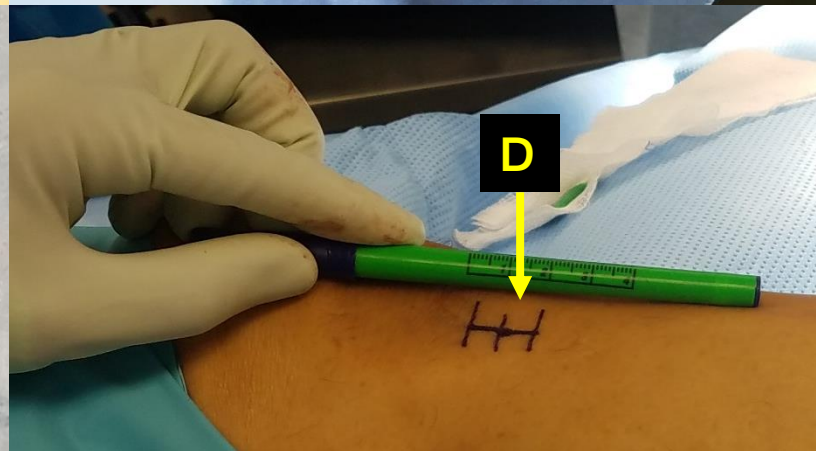
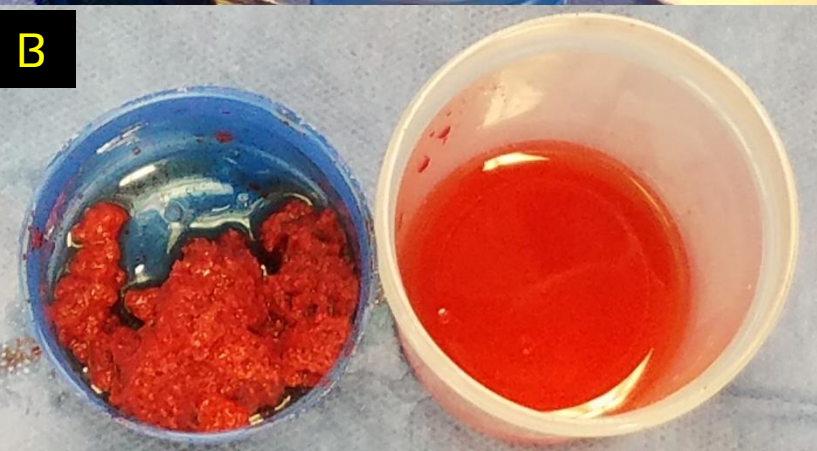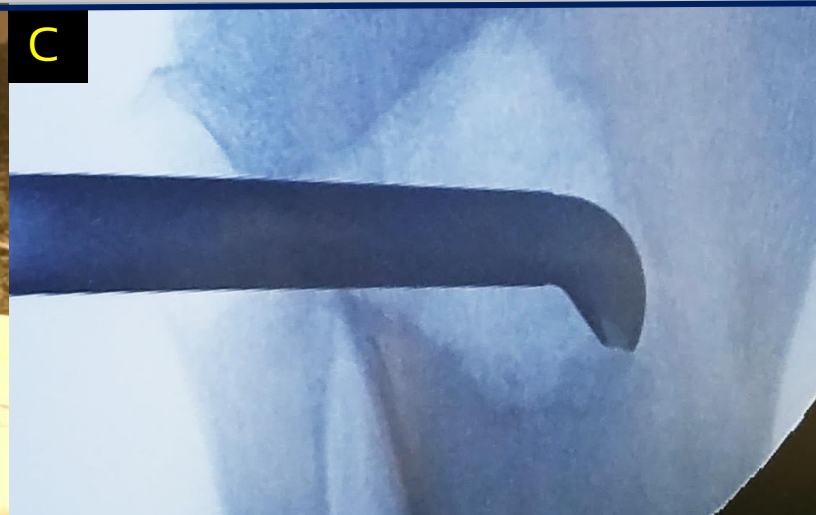
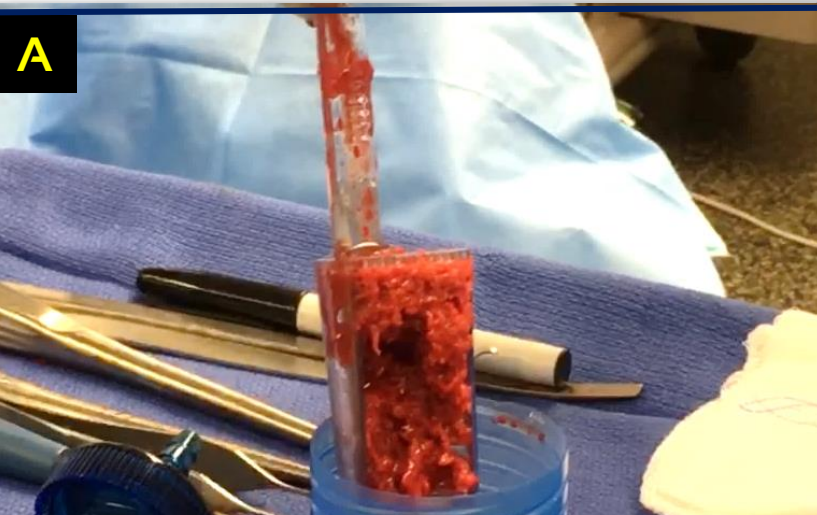


# CASE STUDY

## Avitus® Bone Harvester PROXIMAL TIBIA HARVEST

- 4 minutes harvest time
- 2 cm incision, Patient: 71 YO, M
- 22 CC's of gold-standard cancellous bone
- 15 CC's of gold-standard bone marrow captured
- Graft was successfully used for a Talonavicular Joint Nonunion
- **Hospital saved \$2,650 on the case!**



- A) Shows Avitus® 22 CC's of gold standard cancellous bone inside the Avitus® Harvester Insert  
B) Shows Avitus® 22 CC's of gold standard cancellous bone separated out from 15 CC's of gold-standard Avitus® Marrow  
C) Shows the Avitus® Harvester under fluoroscopy harvesting through a minimally invasive entry  
D) Shows 2cm incision line the procedure was performed through