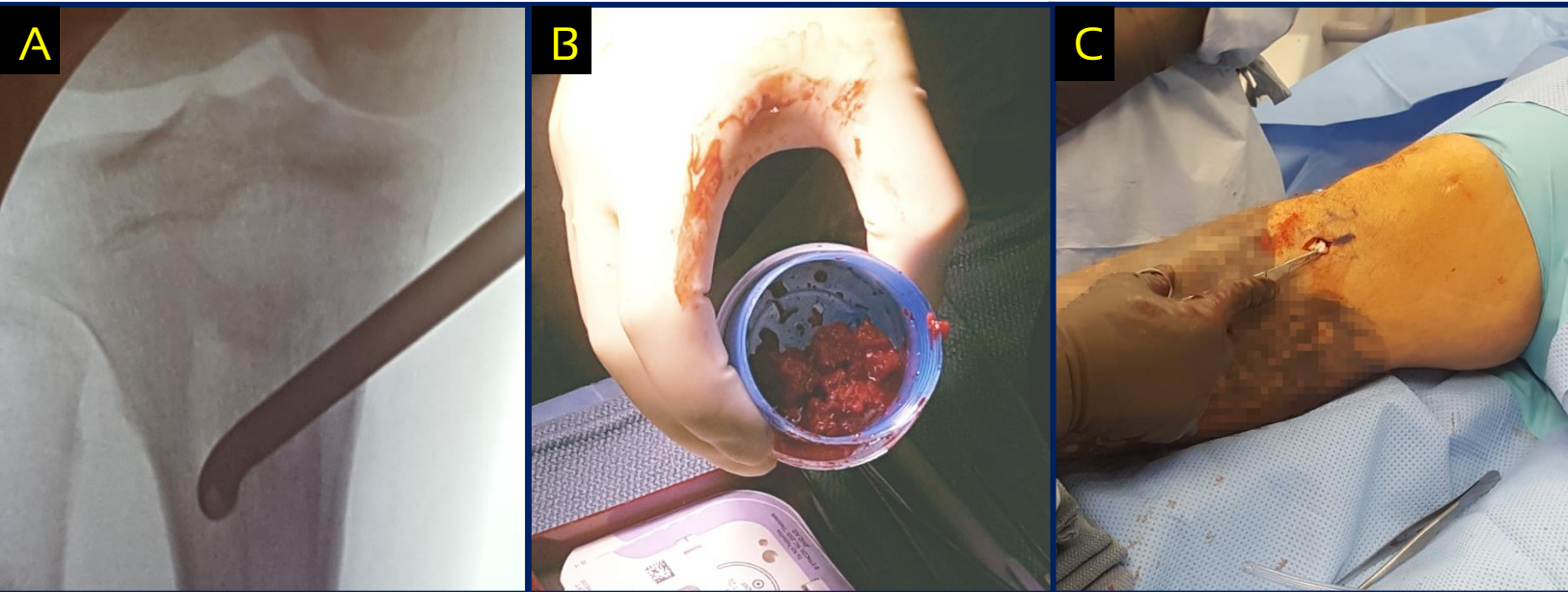


CASE STUDY

Avitus® Bone Harvester PROXIMAL TIBIA HARVEST

- 10 CC's of gold-standard cancellous bone
- 1 cm incision
- 5 minutes harvest time
- Graft was successfully used for Tibiotalar Joint Fusion and Subtalar Fusion
- No bone graft substitutes required
- Hospital saved \$6,300 in this surgery



- A) Radiograph of Avitus® Bone Harvester within harvest site
- B) Avitus® cancellous bone removed from the device
- C) Gel-foam backfill of 1-cm incision site