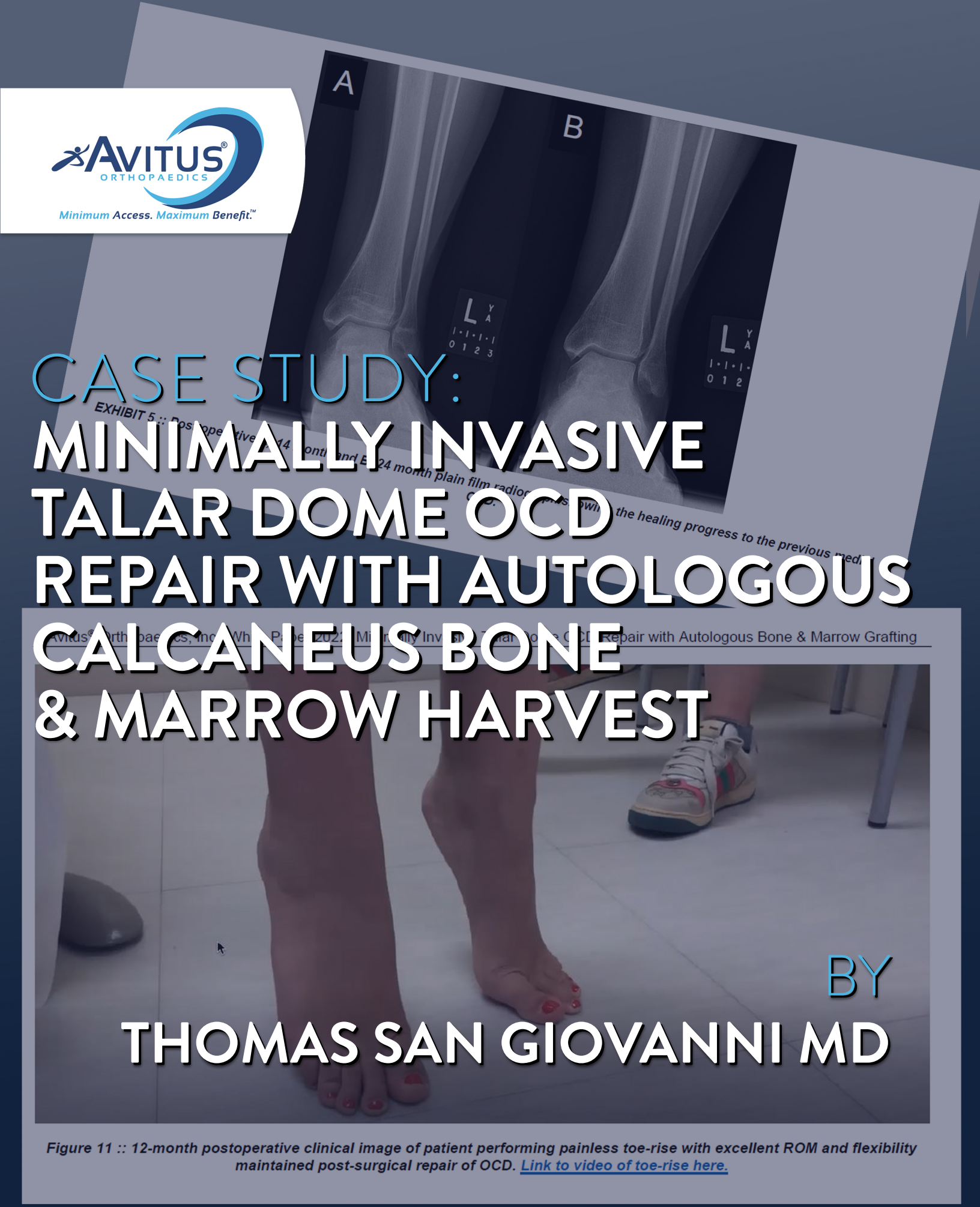

CASE STUDY:
MINIMALLY INVASIVE TALAR DOME OCD REPAIR WITH AUTOLOGOUS CALCANEUS BONE & MARROW HARVEST

BY
THOMAS SAN GIOVANNI MD

Figure 11 :: 12-month postoperative clinical image of patient performing painless toe-rise with excellent ROM and flexibility maintained post-surgical repair of OCD. Link to video of toe-rise here.

CASE STUDY: Minimally Invasive Talar Dome Osteochondral Defect (OCD) Repair with Autologous Bone and Marrow Grafting

By Thomas San Giovanni MD

Associate Professor of Orthopedic Surgery
Florida International University College of Medicine
Foot & Ankle Division, Sports Medicine

Miami Orthopedics & Sports Medicine Institute
Baptist Health South Florida
Miami, Florida USA

CLINICAL PRESENTATION

The patient presented as a 14-year-old female with a symptomatic medial talar dome osteochondral defect (OCD) that failed to improve following previous surgical intervention at another institution one year prior. She had undergone an arthroscopic microfracture procedure of the lesion but remained symptomatic with joint-related symptoms of pain and dysfunction. Her symptoms worsened over time with an increase in pain frequency and intensity. Pain was predominantly activity-related but began to affect her daily walking activities, requiring use of either a boot or stirrup ankle brace when exacerbated. Her presenting preoperative radiolucency within the subchondral region of the medial talar dome (**Figure 1**).

Patient was referred to our center for further care and definitive treatment. Of note, the patient is a state level competitive volleyball athlete that looks to continue competing at a high level. Preoperative magnetic resonance imaging (MRI) demonstrated significant residual bone marrow edema and OCD pathology at the medial talus (**Figure 2**). Patient and her parents elected for revisional talar OCD repair with microfracture, debridement/curettage and autologous bone and bone marrow grafting through a minimal approach.

OPERATIVE TECHNIQUE

An ankle arthroscopy was performed, and the osteochondral lesion was identified along the medial talar dome. The lesion was debrided arthroscopically and then adequately prepared for repair by thoroughly curetting the surface edges of the defect of any avascular fibrinous appearing bone This typically corresponded with color change from pale whitish-yellow bone to that of the more typical healthy cancellous bone appearance. The lesion was measured with dimensions recorded as 16 mm (anterior to posterior) x 10 mm (medial to lateral) x 8 mm (depth)**.** The base and walls of the defect were then dimpled in a grid pattern with various angled micropicks **(Figure 3 , 4)**. The tourniquet was then deflated to ensure that the lesion was prepped adequately by displaying perfused bleeding surface edge along the walls and basement of the lesion. The bone graft harvest was performed via a small incision made along the lateral calcaneus to allow for harvesting of autologous bone and non-diluted liquid marrow (**Figure 5**)**.** The Avitus® Bone Harvester was used to harvest adequate volume of autologous cancellous bone and marrow in a minimally invasive manner from the ipsilateral posterior calcaneal body (6mm harvester). The medial arthroscopy portal was extended slightly to convert to a mini-arthrotomy allowing for better visualization and placement of the graft to fill the entire defect. The ankle was then plantarflexed and the medial talar dome defect was easily accessed. Some of the non-diluted bone marrow was injected into the defect to bathe the walls allowing the marrow to seep into the adjacent regions through the micropick dimples created in the debrided defect. Next, the Avitus® autologous cancellous bone graft was packed into the osteochondral defect from its depth to the flush level of the subchondral bone surface (**Figure 6**). After packing was completed, additional Avitus® non-diluted bone marrow as applied. Preparation of the final top layer consisted of mixing equal parts plasma concentrated A2M (Cytonics APIC) and Avitus® non-diluted bone marrow with dry allograft cartilage

extracellular matrix powder until a thick homogenous paste-like consistency was obtained. Mixture was applied to fill the topmost layer flush with the cartilage. The remaining autologous plasma A2M was injected intra-articularly and then a fibrin gel was used over the filled OCD's top layer as a protective biological sealant. The ankle was held still in position for 5 minutes to allow the plasma fibrin gel to form a protective gel barrier.

Postoperative management involved a nonweightbearing splint for two weeks after which the sutures were removed. The patient was then placed in a removable boot and allowed to begin early gentle range of motion exercises yet remained nonweightbearing until 4 weeks postop. At 4 weeks postop, she was allowed protected weightbearing with a walking boot for another 4 weeks before transitioning out to an air-stirrup type ankle brace and supportive sneaker. Guided physical therapy was initiated at 4 weeks postop once she was placed in a boot and continued for several months as progressive gains were noted.

POST-OPERATIVE FOLLOW UP

The patient had an uneventful recovery period and was able to return to competitive sports. Follow-up radiographic images were taken during different stages of healing (**Figure 7,8**), along with an MRI at 6 months (**Figure 9**). No post-operative pain was observed by the patient at the lateral calcaneal harvest site. Further images were obtained of the calcaneal graft harvest site to show its progression of consolidation and trabeculation (**Figure 10**). . At the beginning of returning to impact activities she had a transient period of mild pain for a few months at the navicular insertion of her posterior tibial tendon yet resolved soon thereafter with strengthening and use of supportive sneakers. Clinical image of patient performing complete toe-rise with excellent ROM and flexibility was noted (**Figure 11**). The patient was last seen at 2-year follow-up from her surgical date. She has remained pain-free, has full active motion and symmetrical strength/function when compared to her uninvolved side. She stated that she feels no limitation with her ankle and has returned to all her sports activities. She and her parents expressed great pleasure with her outcome and how the mechanical and biological factors of her ankle's condition were addressed.

CONCLUSION

The Avitus® Bone Harvester provides the ability to harvest autologous cancellous bone and non-diluted liquid bone marrow quickly through a minimal approach. The harvest site had no pain post-operatively. Graft incorporation in the underlying previous lesion site is paramount for the site to accept the load and stress of the ankle joint during ambulation. The additional marrow collected with the Avitus® provides rich biology to augment with cartilage repair biomaterials. This helps to ensure pain-free joint ROM and return to activity. The Avitus® Bone Harvester is our standard for addressing the mechanical and biological needs of our OCD repair cases.

Thomas San Giovanni MD

Associate Professor of Orthopedic Surgery
Florida International University College of Medicine
Foot & Ankle Division, Sports Medicine

Miami Orthopedics & Sports Medicine Institute
Baptist Health South Florida
Miami, Florida USA

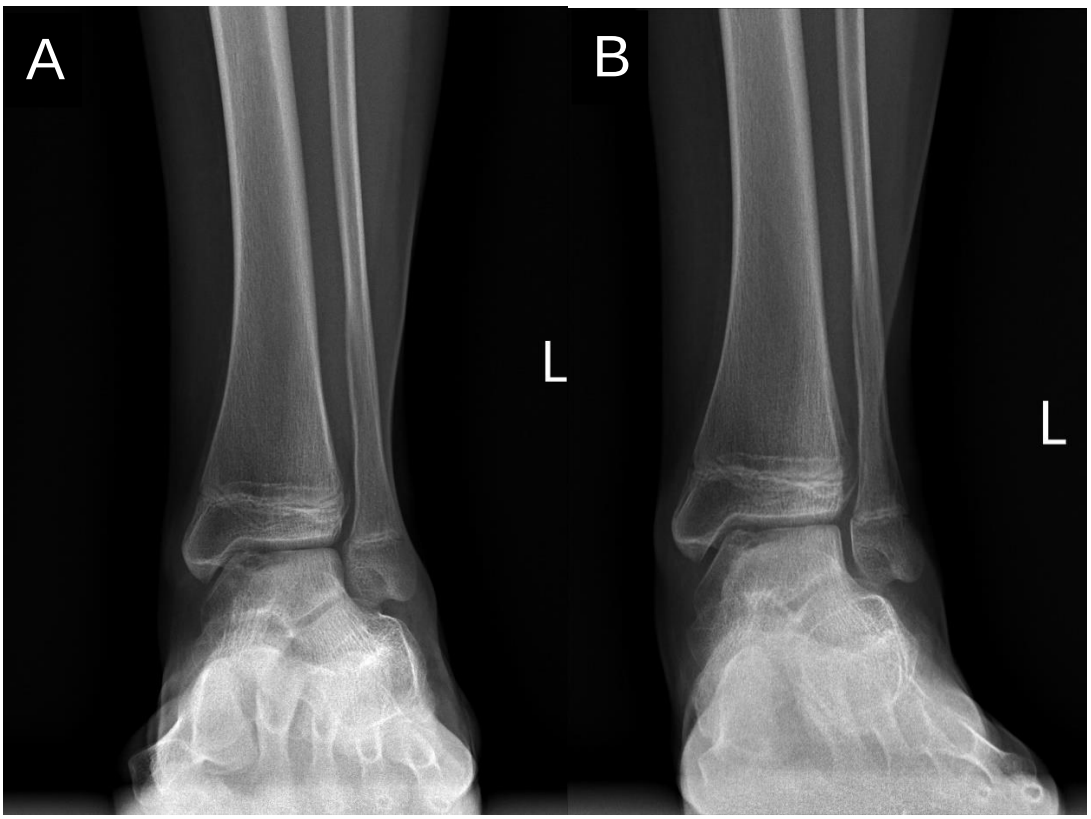

Figure 1 :: Pre-operative A) AP and B) mortise plain radiographs of a large medial talar dome osteochondral lesion/defect.

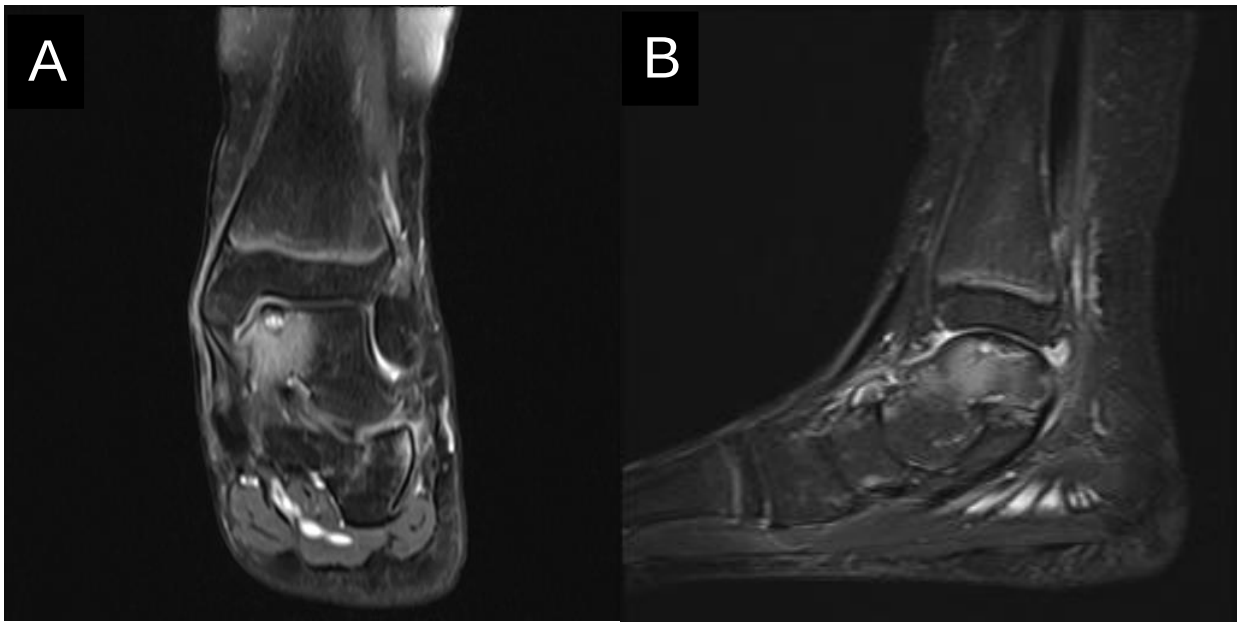

Figure 2 :: Pre-operative A) Coronal and B) Sagittal plane MRI demonstrating large medial talar dome lesion/defect with significant marrow edema & reaction.

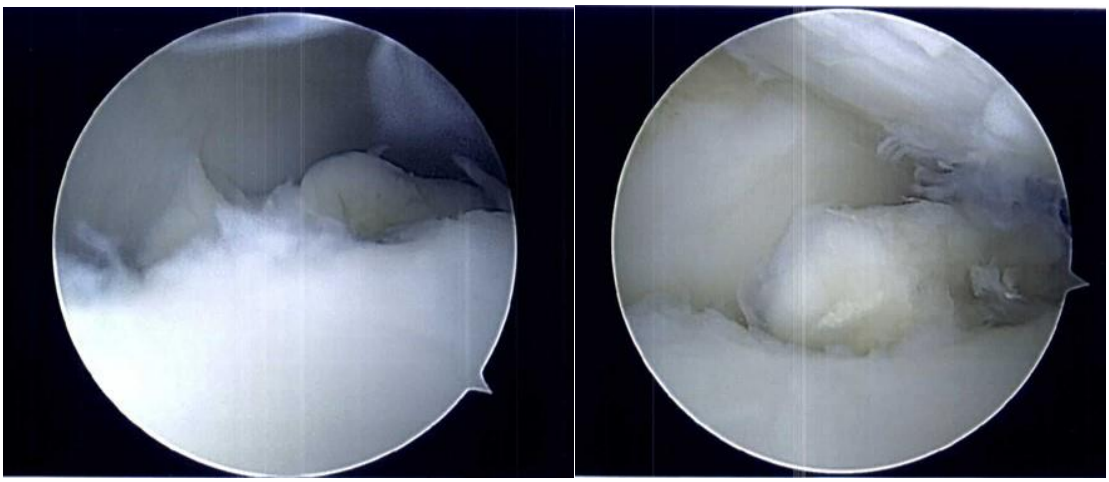

Figure 3 :: Arthroscopic view of medial talar dome osteochondral lesion

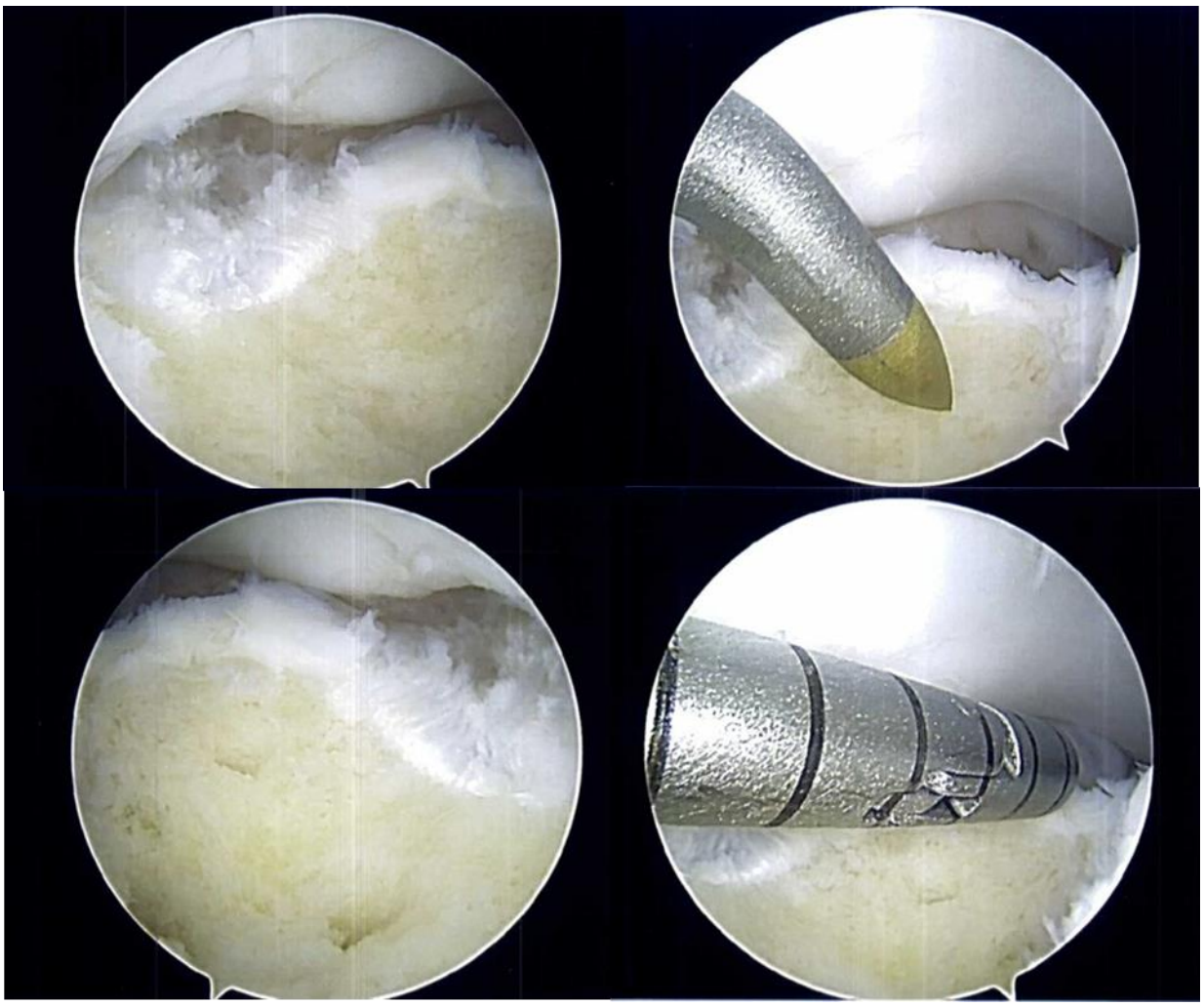

Figure 4 :: Lesion prepped by removal of fibrinous avascular appearing subchondral bone until level of more normal color and consistency (tourniquet still up in images though eventually deflated to confirm prep to level of perfused bone with good bleeding surfaces or fatty marrow observed), lesion dimensions measured for filling.

Figure 5 :: Intra-operative clinical image of autologous bone graft and non-diluted liquid bone marrow harvested with the Avitus® Bone Harvester.

Figure 6 :: Intra-operative clinical image of autologous bone graft packed filling entire defect up to and flush with the adjacent subchondral level prior to Cartilage graft and fibrin sealant.

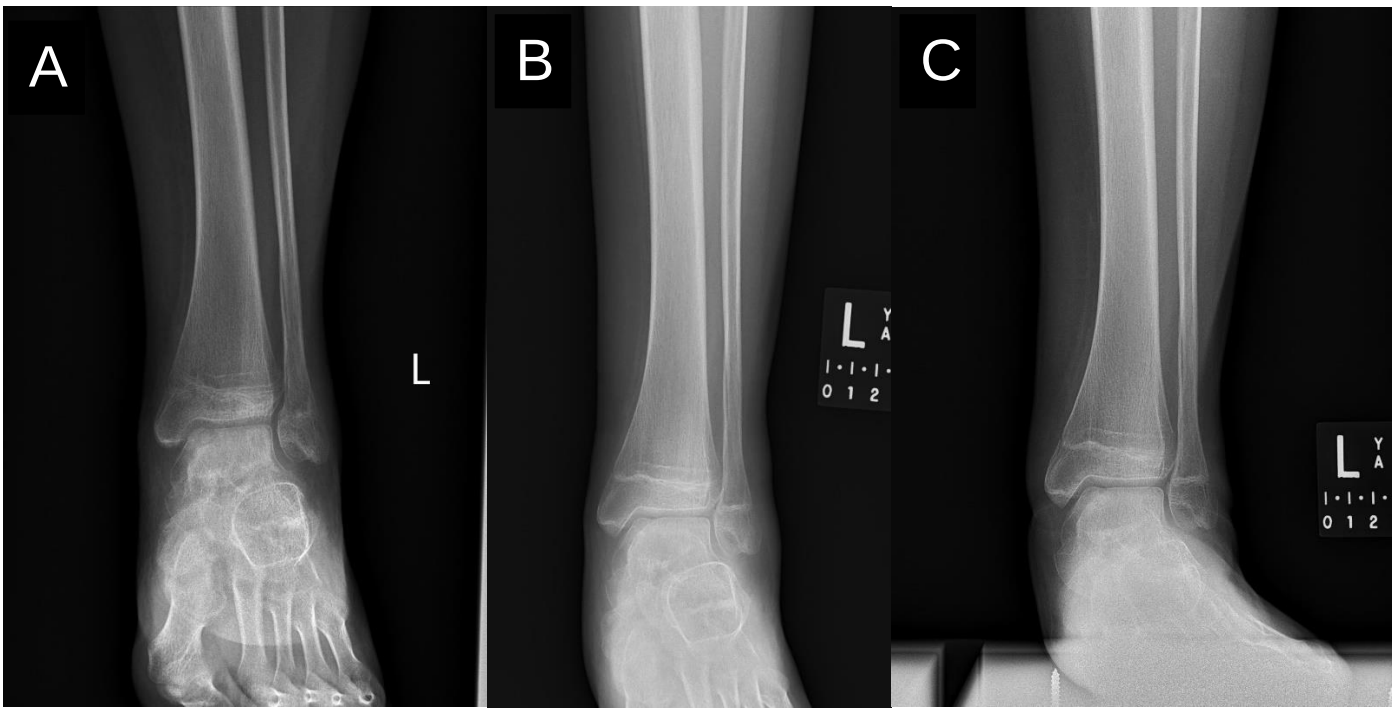

Figure 7 :: Post-operative A) 1 month B) 3 month and C) 6-month plain film radiograph showing the healing progress to the previous medial talar dome OCD.

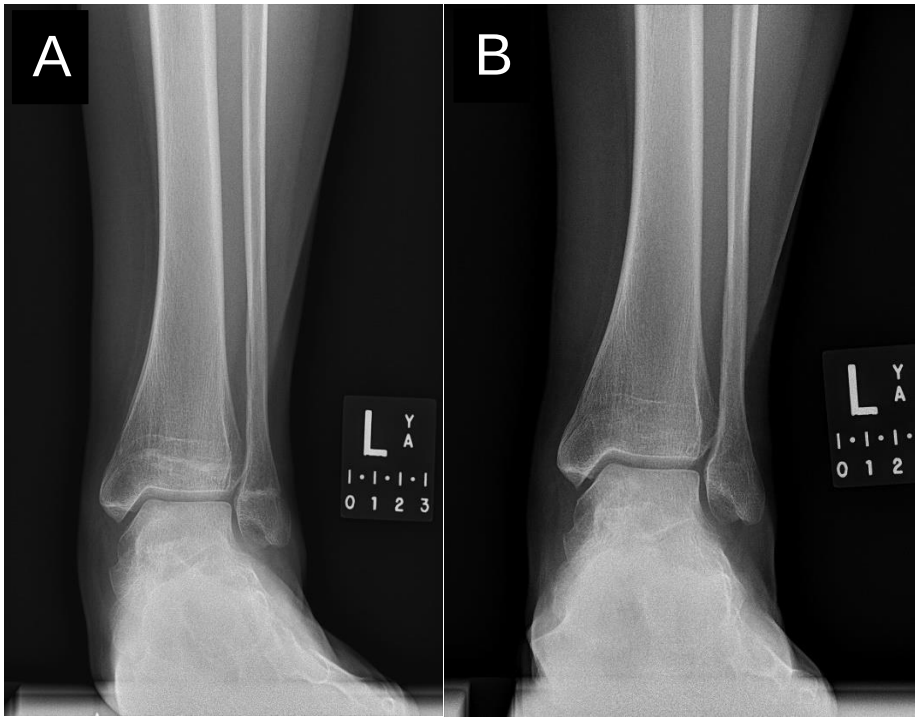

Figure 8 :: Post-operative A) 14 month and B) 24-month plain film radiograph showing the healing progress to the previous medial talar dome OCD.

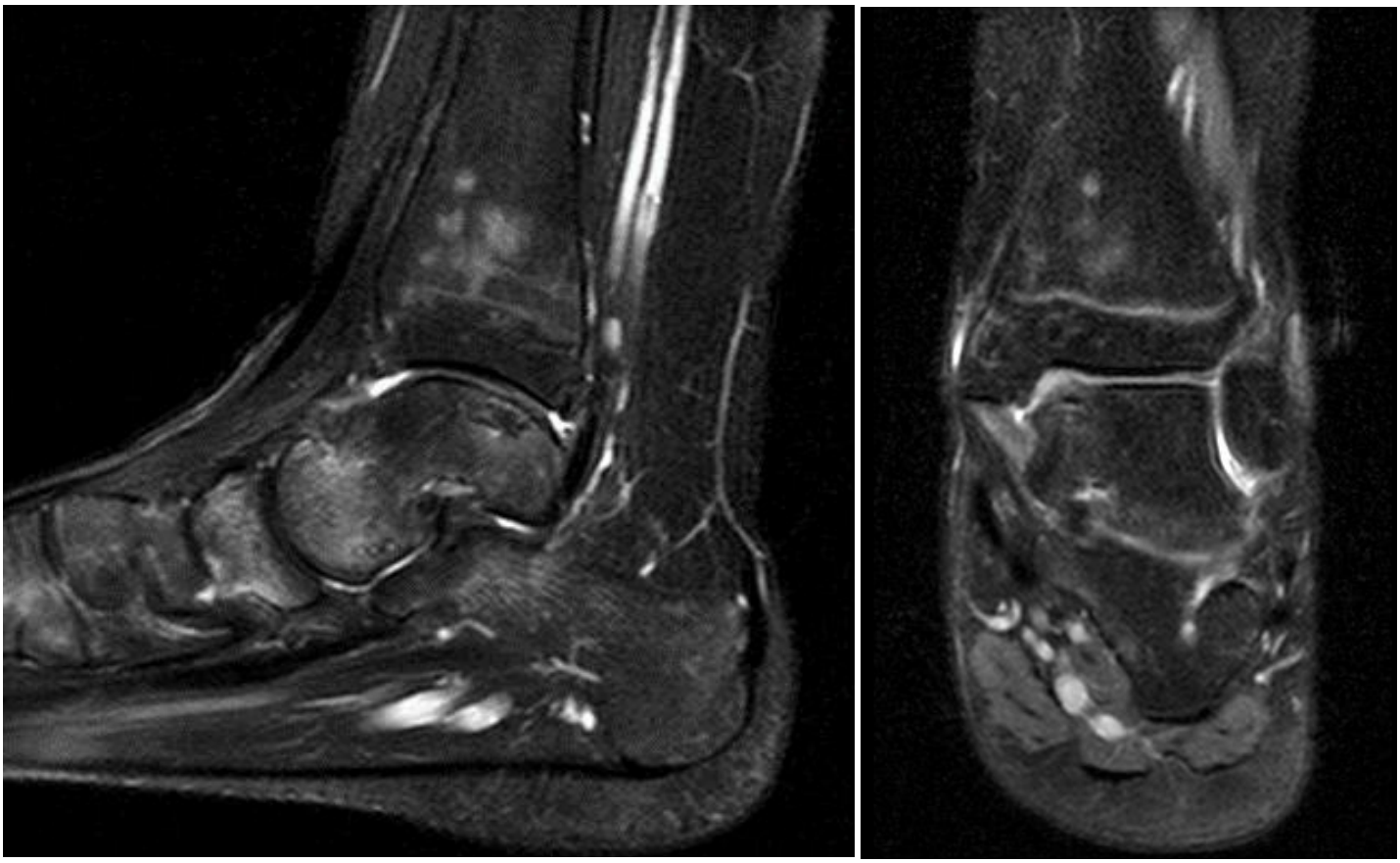

Figure 9 :: post-operative 6-month MRI demonstrating near complete healing of surgically treated OCD and resolution of bone marrow edema.

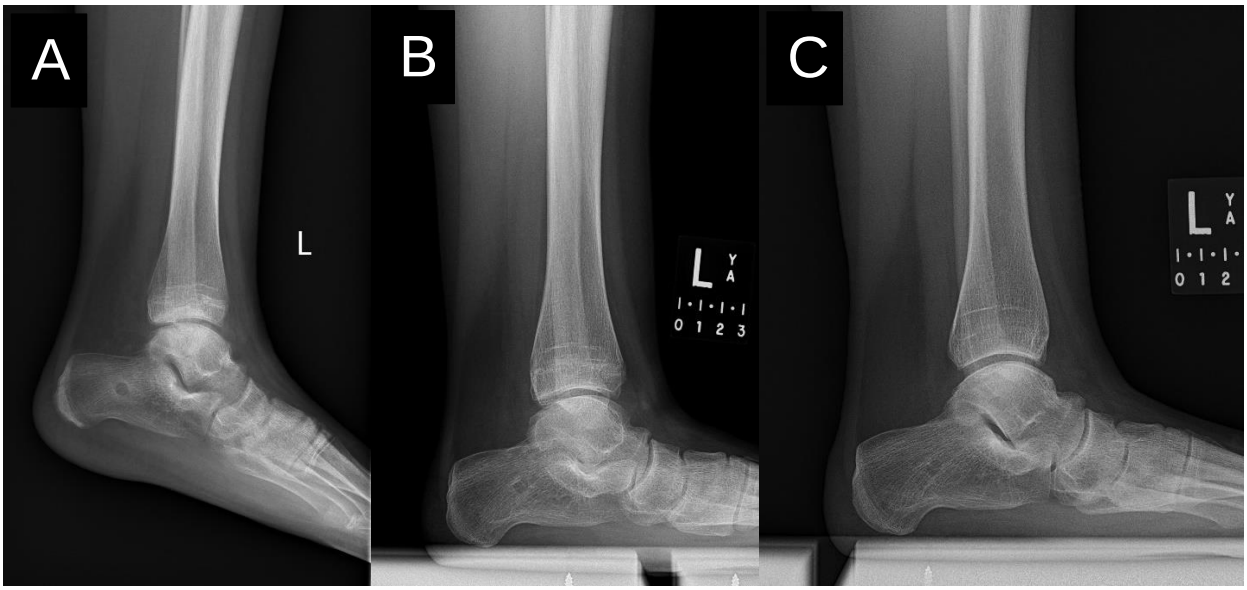

Figure 10 :: A) 1 month B) 14 month and C) 24-month post-operative plain film radiographs showing the healing progress to the calcaneal harvest site. Patient had no post-op pain at the harvest site. No backfill was used.

Figure 11 :: 12-month postoperative clinical image of patient performing painless toe-rise with excellent ROM and flexibility maintained post-surgical repair of OCD. Link to video of toe-rise here.