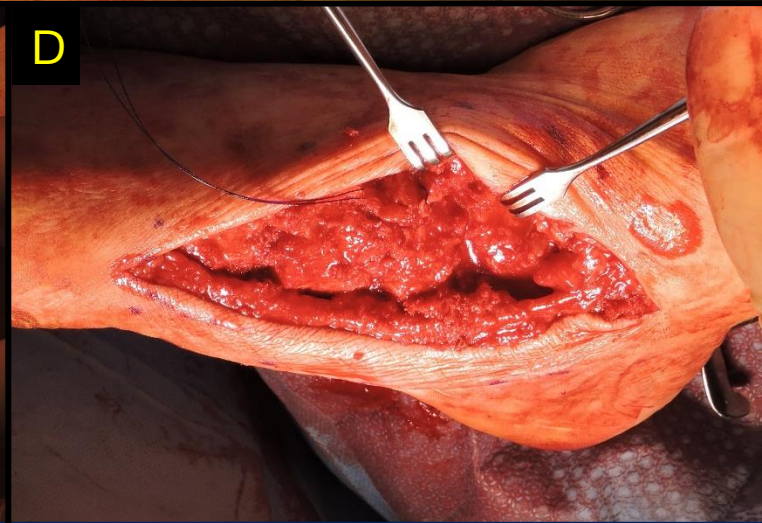
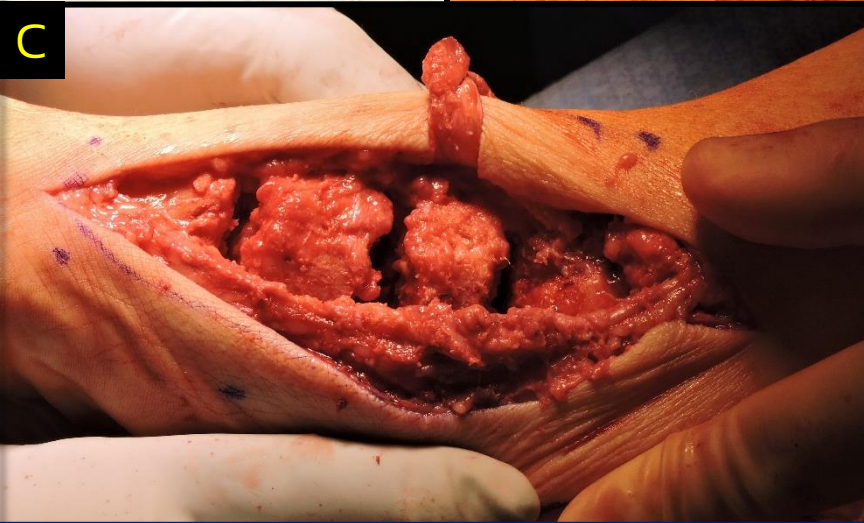
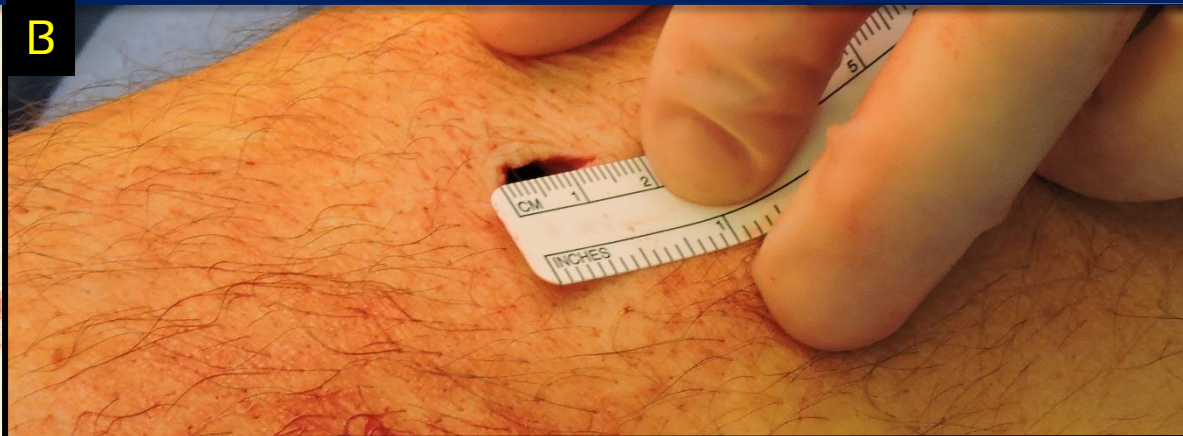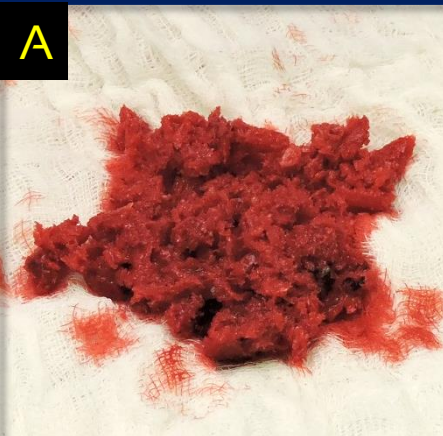

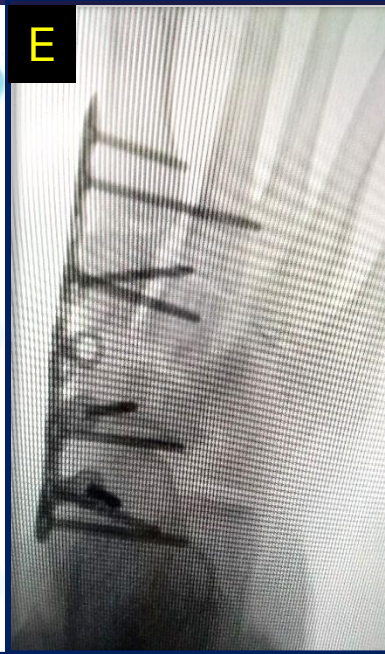
CASE STUDY


Avitus® Bone Harvester PROXIMAL TIBIA HARVEST

- 1.5 cm incision
- 9 minutes harvest time
- 35 CC's of **gold-standard** cancellous bone
- 35 CC's of **gold-standard** bone marrow captured
- Patient reported "no pain whatsoever" at harvest site 1 week post-op
- Graft was successfully used for a Talonavicular to First Metatarsal / Charcot Fusion
- No synthetics used, hospitals saved \$9,600!



- A) Shows 35 CC's of Avitus® gold standard cancellous bone after separating from marrow.
- B) Shows harvest site incision
- C) Shows 3 fusion sites that needed to be filled
- D) Shows fusion sites packed!
- E) Show post hardware, finished product!

sales@avitusortho.com



Minimum Access. Maximum Benefit.™